



PATIENT

Biscuit Prieto

SPECIES

Feline

BREED

DSH

SEX

Male Neutered

AGE

3 years

WEIGHT

10.5lbs

INTERPRETED BY

Maggie Machen Lamy,
DVM, DACVIM
(Cardiology)

IMAGING PERFORMED BY

Liz Berndt, DVM

HOSPITAL NAME

College Park Animal
Hospital – VetCor

REFERRING VET

Dr. Liz Berndt

INVOICE

46989

DATE

2/25/26

PRESENTING CLINICAL SIGNS

History: Screening exam. Labs: pending. Sedated with Gabapentin, Alfaxalone and Torb.

ECHOCARDIOGRAM FINDINGS

2D, m-mode, color flow and doppler imaging is available. The left ventricular wall is normal in dimension. The endocardium appears normal. The papillary muscles are normal in size and architecture. The left atrium is normal in size. The right atrium is normal in size. The right ventricle appears normal. The mitral valve is normal in structure and mobility. No MR seen. Normal flow through both the RVOT and LVOT. No obvious TR, AI or PI. No congenital defects are observed. No pleural or pericardial effusion seen. No obvious cardiac tumors.

CARDIAC CHART

FELINE CARDIAC PARAMETERS	BODY WEIGHT (kg)	HR (BPM)	IVSd (cm) <small>(Moise, Pipers)</small>	LVIDd (cm) <small>(Moise, Pipers)</small>	LVWd (cm) <small>(Moise, Pipers)</small>	FS (%)	EF (%)
NORMAL PARAMETER	-----	150-240	0.35-0.55	<2 (mean 1.5)	3.5-0.55	35-67	80-100
PATIENT	4.8	NM	0.32	1.36	0.38	52	90
FELINE CARDIAC PARAMETERS	LA/AO <small>(Boon)</small>	LA/AO HEART BASE (Swe) <small>(Abbott)</small>	LA 2D short axis Base view (cm) <small>(Abbott)</small>		LVOT VEL (m/s)	RVOT VEL (m/s)	E max (m/s)
NORMAL	<1.5	<1.3	<1.2		<1.6	<1.3	<0.9
PATIENT	NM	1.1	1.0		0.8	0.8	NM

**Note: All measurements based upon multi-modal images and methods. An average value is reported.
Adapted from June Boon, Veterinary Echocardiography, 1998
Abbott J & MacLean H JVIM 2006;20: 111-119, Moise et al. Am J Vet Res 47:1476, 1986. Pipers et al. Am J Vet Res 40:882, 1979.*

INTERPRETATION OF THE FINDINGS & FURTHER RECOMMENDATIONS

Overtly normal cardiac structure and function. The LV wall thickness is normal and there is no evidence of elevated left atrial pressure. No significant valve leaks are identified, and flow through the great vessels is normal. No obvious congenital issues are documented.

Given these findings, no medications are indicated. It is important to note that phenotypic HCM can develop at any phase of life in cats (particularly in this predisposed breed) and often does not accompany a heart murmur or PE abnormalities. Periodic screening is ideally recommended in all cats.

No cardiac contraindication for general anesthesia at this time.

Recommend recheck echocardiogram in 1 year to assess for development of disease, sooner if a murmur/gallop or clinical signs develop in the interim.



PATIENT

Biscuit Prieto

SPECIES

Feline

BREED

DSH

SEX

Male Neutered

AGE

3 years

WEIGHT

10.5lbs

INTERPRETED BY

Maggie Machen Lamy,
DVM, DACVIM
(Cardiology)

IMAGING PERFORMED BY

Liz Berndt, DVM

HOSPITAL NAME

College Park Animal
Hospital – VetCor

REFERRING VET

Dr. Liz Berndt

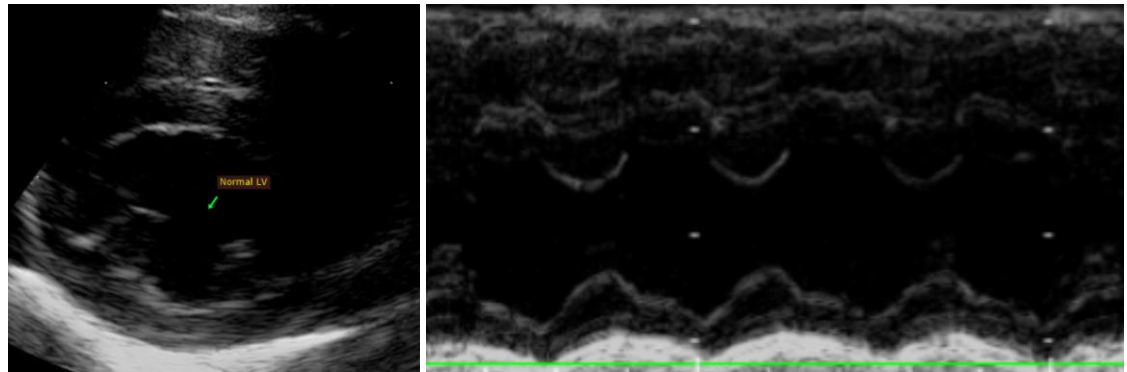
INVOICE

46989

DATE

2/25/26

IMAGES



The information and recommendations provided are based on the images presented by the referring veterinarian. No evaluation can be communicated regarding pathology that was not visible in the image/video clips provided.

Thank you for this referral. This report was generated using transcription software, and minor dictation errors may be present. If the clinical or image interpretation does not parallel your findings or if I can be of any further assistance, please contact me.

Maggie Machen Lamy, DVM
Diplomate of the American College of Veterinary Internal Medicine (Cardiology)
info@sonopath.com